



PediGuard[®]

Placing Navigation Back in Your Hands

Case Report

Secure pedicle screw placement
in the thoraco-cervical spine

Ely Ashkenazi, M.D.
Michael Millgram, M.D.

Israel Spine Center
Assuta Hospital
Tel Aviv, Israel

SpineGuard[™]
Make spine surgery safer

Case

13 y/o female with a painless progressive congenital thoraco-cervical scoliosis C7-T8 of 68° with an upper thoracic hump and an unremarkable neurological examination.

Neuroaxis abnormalities were excluded on MRI imaging.

Bony abnormalities included a unilateral bar T3-5 and concave rib fusion T2-5.

Triradiate cartilage closure was evident on X-rays.

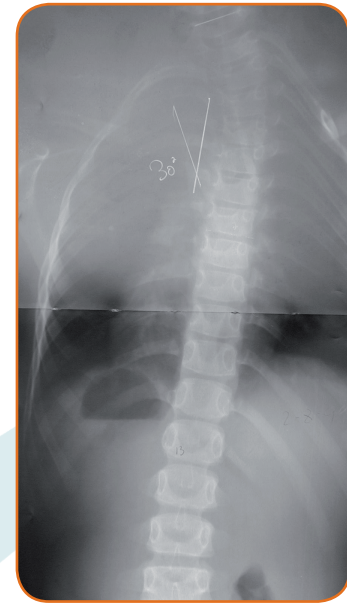
Risser score = 0.

Operative Goal

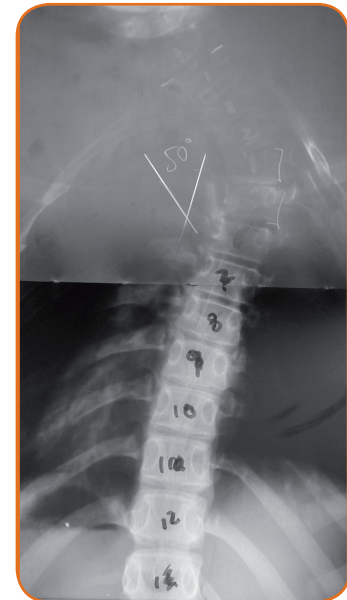In situ fusion C7-T9 using segmental pedicle screw instrumentation.

Pre-Operative Assessment

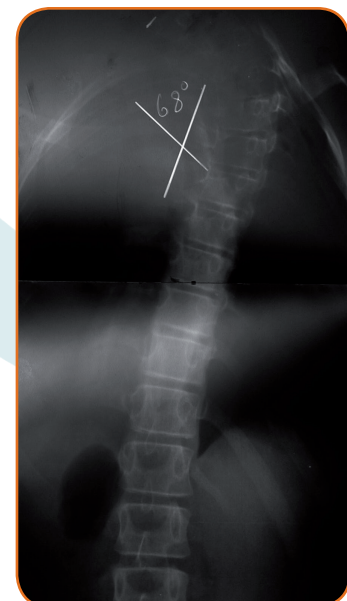
Pre-operative assessment for associated congenital abnormalities was negative.



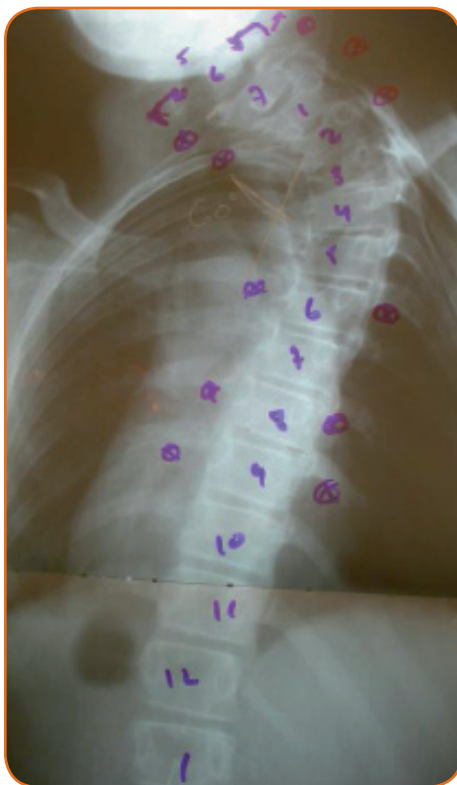7 y/o :
Thoraco-cervical scoliosis C7-T8 of 30°



11 y/o :
Thoraco-cervical scoliosis C7-T8 of 50°



13 y/o :
Thoraco-cervical scoliosis C7-T8 of 68°



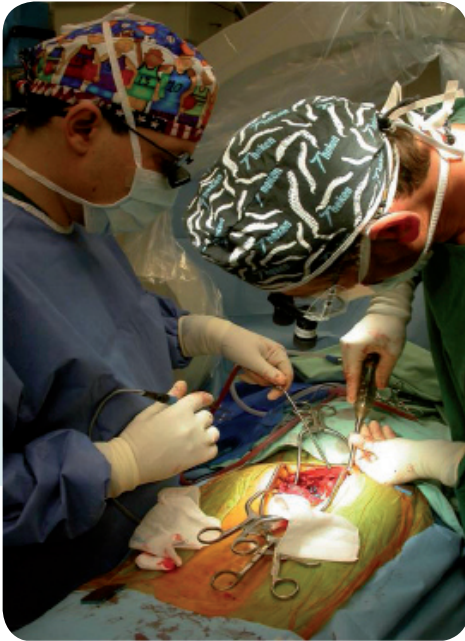Frontal X-Ray view

Pedicle Preparation Instrumentation: PediGuard®

PediGuard®, a pedicle screw pilot hole preparation instrument, was used to assist accurate pedicle screw placement.

PediGuard® provides audible and visual feedback in response to local tissue conductivity changes.

This feedback allows the surgeon to discriminate between different types of tissue in contact with the tip.



Pedicle Preparation Technique

Pedicle entry points were determined anatomically and with preoperative CT imaging assistance.

An awl created a bony crater at the entry point and the PediGuard® was then employed to create a pre-hole.

PediGuard® was passed down the pedicle by rotating the handle back and forth to drill through the cancellous bone.

The audio signals of the device guided the drilling down the pedicle, avoiding cortical breach.

Pedicle screws of appropriate diameter and length were then advanced down the pedicle.

Clinical Summary

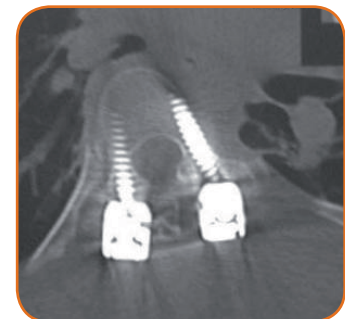
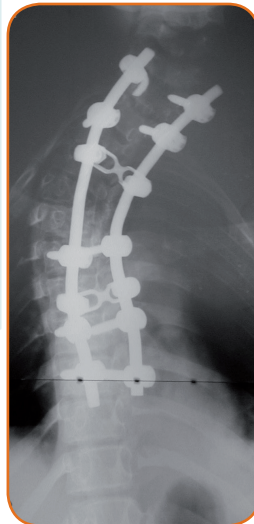
PediGuard® allowed accurate insertion of the screws in a child presenting with small distorted pedicles.

In situ fusion C7-T9 was undertaken for cervico-thoracic congenital scoliosis with pedicle screws placed at C7 and T1 on the left side, T2 on the right side and bilaterally at T6, T8 and T9. Placement of rods and bone grafts completed the fixation and fusion.

Post Operative

Post operative X-rays and CT imaging demonstrated accurately placed screws at all levels.

At two years follow-up, the patient is solidly fused without curve progression, is neurologically intact and pain free.



14 y/o :
1 year post-op AP X-Ray showing position of screws



Distributed by

www.spineguard.com

SpineGuard™ S.A.
5-7, rue de l'Amiral Courbet
94160 Saint-Mandé - France
Phone: +33 1 45 18 45 19
Fax: +33 1 45 18 45 20

SpineGuard™
Make spine surgery safer

SpineGuard™ Inc.
301 Howard Street, Suite 970
San Francisco, CA 94105 - USA
Phone: +1 415 512 2500
Fax: +1 415 512 8004

CE 0123

Caution: See package insert for labeling limitations, intended uses, relevant warnings, precautions, side effects and contraindications.
Federal (USA) law restricts the sale and use of this device to a prescription of a physician.

GPI CR109 October 2009