

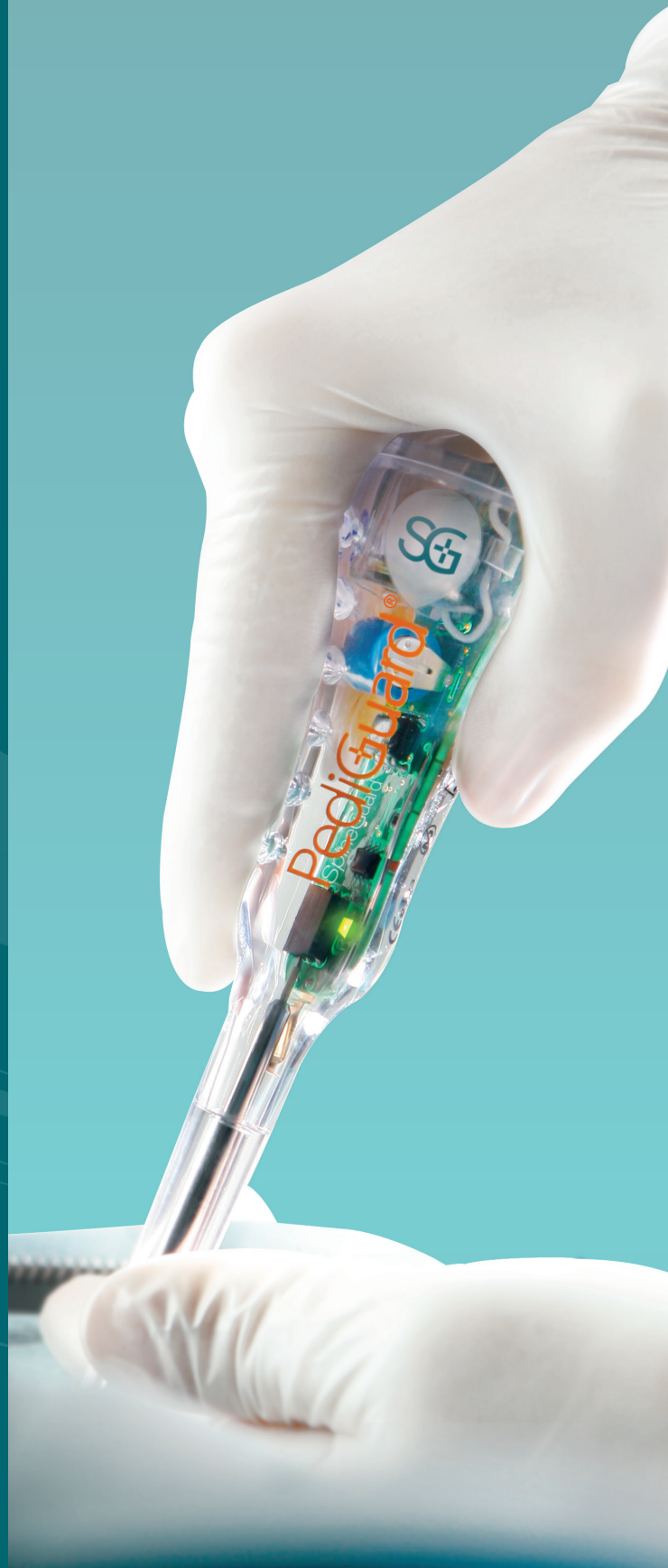Case Report

Dystrophic Scoliosis in Neurofibromatosis - Type 1 (NF-1)

Peter G. Gabos, MD

Co-Director,
Spine and Scoliosis Center
Nemours/Alfred I. duPont Hospital for Children
Wilmington, Delaware, USA

SpineGuard[®]
Making spine surgery safer



Case

10 year old premenarchal female presented for spine evaluation with no prior medical history, normal neurologic exam, kyphoscoliosis in the thoracic spine with right trunk shift. Her skin exam showed multiple café-au-lait spots and inguinal and axillary freckling.

Plain radiographs (Fig. 1a and 1b) demonstrate a short, sharp thoracic scoliosis with dystrophic changes in the ribs and spine. MRI showed no intraspinal or intracranial tumors/neurofibromas. CT scan showed marked vertebral deformity with multiple “thread-like” pedicles (Fig 2). The 5th and 6th rib heads intruded into the spinal canal and indented the spinal cord (Fig. 3).

Patient was diagnosed with neurofibromatosis type 1 (NF-1).

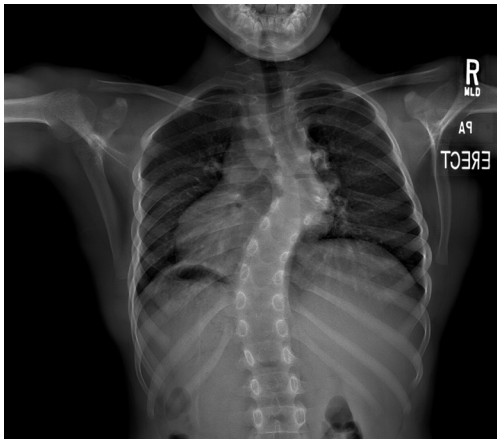

Fig. 1a

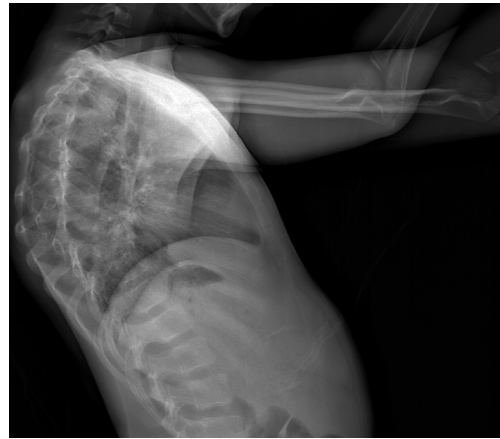

Fig. 1b

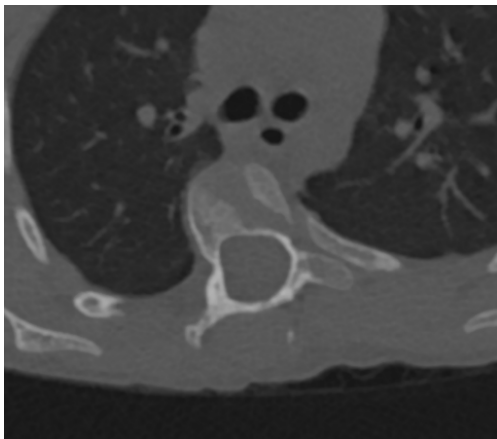


Fig. 2

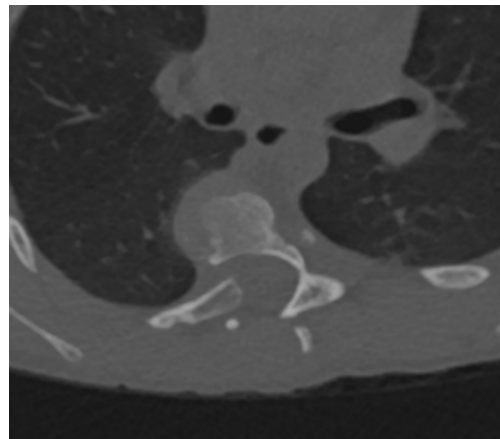


Fig. 3

Treatment Goals

Prevent progressive spinal deformity and collapse, correct deformity, restore spino-truncal balance, extract intraspinal rib heads to prevent catastrophic paralysis, and achieve circumferential (360 degree) apical fusion due to known high pseudarthrosis rate in NF-1.

Surgical Plan

An anterior apical discectomy and fusion from T3 to T10 via right thoracotomy was performed. Intraspinal ribs 5 and 6 were resected from anterior approach. Posterior selective thoracic fusion with instrumentation from T2 to T10 was performed.

Pedicle Preparation Instrumentation: PediGuard® probe

The PediGuard probe with DSG® (Dynamic Surgical Guidance) Technology is a stand-alone, pedicle preparation instrument, requiring no additional equipment. It differentiates between tissue types (cancellous, cortical or soft tissue) based on their electrical conductivity via a bipolar sensor embedded at the tip of each device. The probe provides real-time audible and visual signals to the surgeon, allowing for anticipation of potential cortical wall breaches and redirection as necessary.



Fig. 4

Pedicle Preparation Technique

The pedicles were cannulated using a PediGuard Curved XS probe (Fig.4) and free-hand technique. At the 5th and 6th vertebral levels, preoperative CT scan showed no safe trajectory for screw placement, so sublaminar bands were utilized at these two levels on the left side. The PediGuard instrument allowed safe placement of screws into the remaining vertebrae. The marked pedicular and vertebral deformity from NF-1 would have made reliance on fluoroscopy difficult. After all screws were placed, an intraoperative ultra low-dose CT scan was performed to verify screw trajectory and length. No screw adjustments were necessary (Fig. 5).

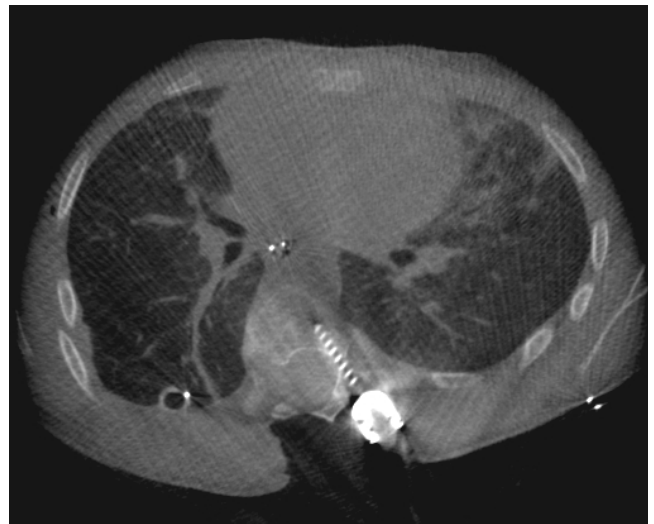

Fig. 5

Postoperative Follow-up

The patient was discharged on postoperative day 4. She enjoyed a slow and steady return to low-impact activities over the following 2 to 3 months. One year after surgery, radiographs demonstrated maintained spinal deformity correction in the coronal and sagittal planes without progressive deformity above or below the instrumented segments. There was no sign of implant failure, loosening or pseudarthrosis (Fig. 6a and 6b).

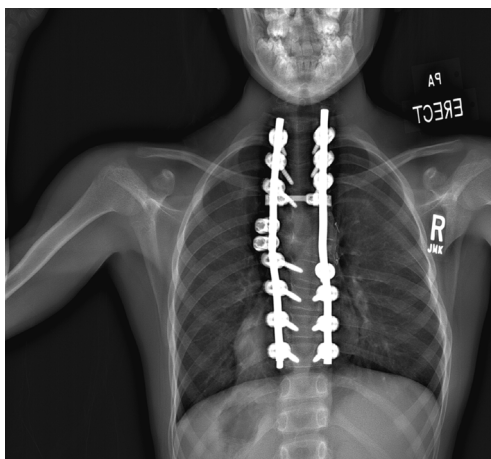


Fig. 6a

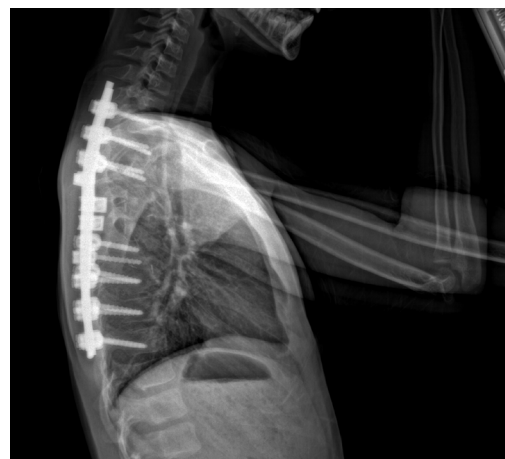

Fig. 6b



DSG Technology:
Simple.
Accurate.
Smart.

SpineGuard®
Making spine surgery safer

www.spineguard.com

SpineGuard® S.A.

10, Cours Louis Lumière
94300 Vincennes, France
Phone: +33 1 45 18 45 19
Fax: +33 1 45 18 45 20

SpineGuard® Inc.

1434 Spruce Street, Suite 100
Boulder, CO 80302
Phone: +1 720 726 8085
Fax: +1 720 726 8001

CE 0123

Caution: See package insert for labeling limitations, intended uses, relevant warnings, precautions, side effects and contraindications.
Federal (USA) law restricts the sale and use of this device to a prescription of a physician.